International Journal of Medical Research

An international, peerreviewed journal of medical and health sciences

Open Access | CC BY 4.0

Volume 3 | Issue 6 | November 2026

REVIEW ARTICLE

Structural and Functional Brain Changes Associated with Chronic Stress: A Systematic Review of Neuroimaging Evidence

Elena Voss; Hiroshi Nakamura; Amina Rahman; Lucas Moreau; Sofia Bergström

PUBLISHED November 2026

HOW TO CITE

Elena Voss; Hiroshi Nakamura; Amina Rahman; Lucas Moreau; Sofia Bergström (2026). Structural and Functional Brain Changes Associated with Chronic Stress: A Systematic Review of Neuroimaging Evidence. International Journal of Medical Research, 3(6), 14.

About the journal

The International Journal of Medical Research (IJOMR) is an openaccess, peerreviewed journal for medical and health sciences. It publishes original research, case reports, review articles and short communications. All articles are free to read and reuse under a Creative Commons Attribution licence.

© 2026 The Author(s) | CC BY 4.0

Structural and Functional Brain Changes Associated with Chronic Stress: A Systematic Review of Neuroimaging Evidence

Hippocampus, Prefrontal Cortex, Amygdala, and Network-Level Alterations

Elena Voss, MD, PhD[1] · Hiroshi Nakamura, MD[2] · Amina Rahman, PhD[3] · Lucas Moreau, MD? · Sofia Bergström, PhD?

[1] *Department of Psychiatry and Neuroimaging, Charité – Universitätsmedizin Berlin, Germany*

[2] *Laboratory of Stress Neurobiology, Kyoto University Graduate School of Medicine, Japan*

[3] *Centre for Brain Health, University of British Columbia, Vancouver, Canada*

? Inserm U1114, University of Strasbourg, France

? Department of Clinical Neuroscience, Karolinska Institutet, Stockholm, Sweden

Correspondence: elena.voss@charite.de

ABSTRACT

Chronic psychological stress produces measurable structural and functional changes in key brain regions involved in emotion regulation, memory, and executive control. This systematic review synthesizes neuroimaging evidence on stress-related alterations in the hippocampus, prefrontal cortex (PFC), amygdala, and large-scale networks. Following PRISMA 2020 principles, PubMed, Scopus, and related databases were searched through 2026; 34 primary studies and reviews were retained. Consistent findings include reduced hippocampal volume (particularly CA1, CA3, and dentate gyrus subfields in some cohorts), dendritic atrophy and cortical thinning in medial and dorsolateral PFC, and mixed but often hyperactivity or volumetric changes in the amygdala. White-matter integrity and connectivity within salience, default-mode, and central-executive networks are frequently altered. Allostatic-load indices correlate with hippocampal and cortical changes in older adults and clinical populations. Effects vary by developmental stage, type and timing of stressor, sex, and presence of psychopathology (depression, PTSD, anxiety). While many changes appear maladaptive, some may reflect adaptive plasticity. Limitations include cross-sectional designs, heterogeneous stress definitions, and small samples. Longitudinal multimodal imaging and mechanistic studies are needed to clarify causality, reversibility, and intervention targets.

Keywords: chronic stress; brain structure; neuroimaging; hippocampus; prefrontal cortex; amygdala; allostatic load; neuroplasticity

1. Introduction

Chronic stress is a major risk factor for psychiatric and somatic illness. Animal and human studies demonstrate that prolonged exposure to stressors reshapes brain morphology and function, particularly in regions rich in glucocorticoid receptors: the hippocampus, amygdala, and prefrontal cortex [1], [2]. These changes are thought to mediate deficits in memory, emotion regulation, and executive function, and to contribute to the pathophysiology of depression, anxiety disorders, and post-traumatic stress disorder (PTSD).

Advances in structural and functional magnetic resonance imaging (MRI), diffusion imaging, and related modalities have allowed increasingly precise characterization of stress-related neuroplasticity in humans. At the same time, the concept of allostatic load—cumulative physiological wear-and-tear from chronic stress—has provided a framework linking systemic biomarkers to brain outcomes [3].

This systematic review summarizes current neuroimaging evidence on structural and functional brain changes associated with chronic stress and related constructs (early-life adversity, allostatic load, and stress-related disorders), with emphasis on the hippocampus, PFC, amygdala, and network-level findings.

2. Methods

The review followed PRISMA-oriented principles [4]. PubMed/MEDLINE, Scopus, and Web of Science were searched from 2010 to late 2026 using combinations of "chronic stress," "allostatic load," "early life adversity," "PTSD," or "depression" with "brain structure," "hippocampus," "prefrontal," "amygdala," "neuroimaging," "MRI," or "connectivity." Peer-reviewed original studies, systematic reviews, and meta-analyses reporting quantitative structural or functional brain measures in relation to stress exposure were eligible. Thirty-four sources were retained for synthesis.

3. Results

3.1 Overview of Evidence Base

The included literature encompasses structural MRI (volumetry, cortical thickness), diffusion imaging, task- and resting-state functional MRI, and multimodal meta-analyses. Figure 1 illustrates the relative emphasis on major brain targets across the synthesized sources.

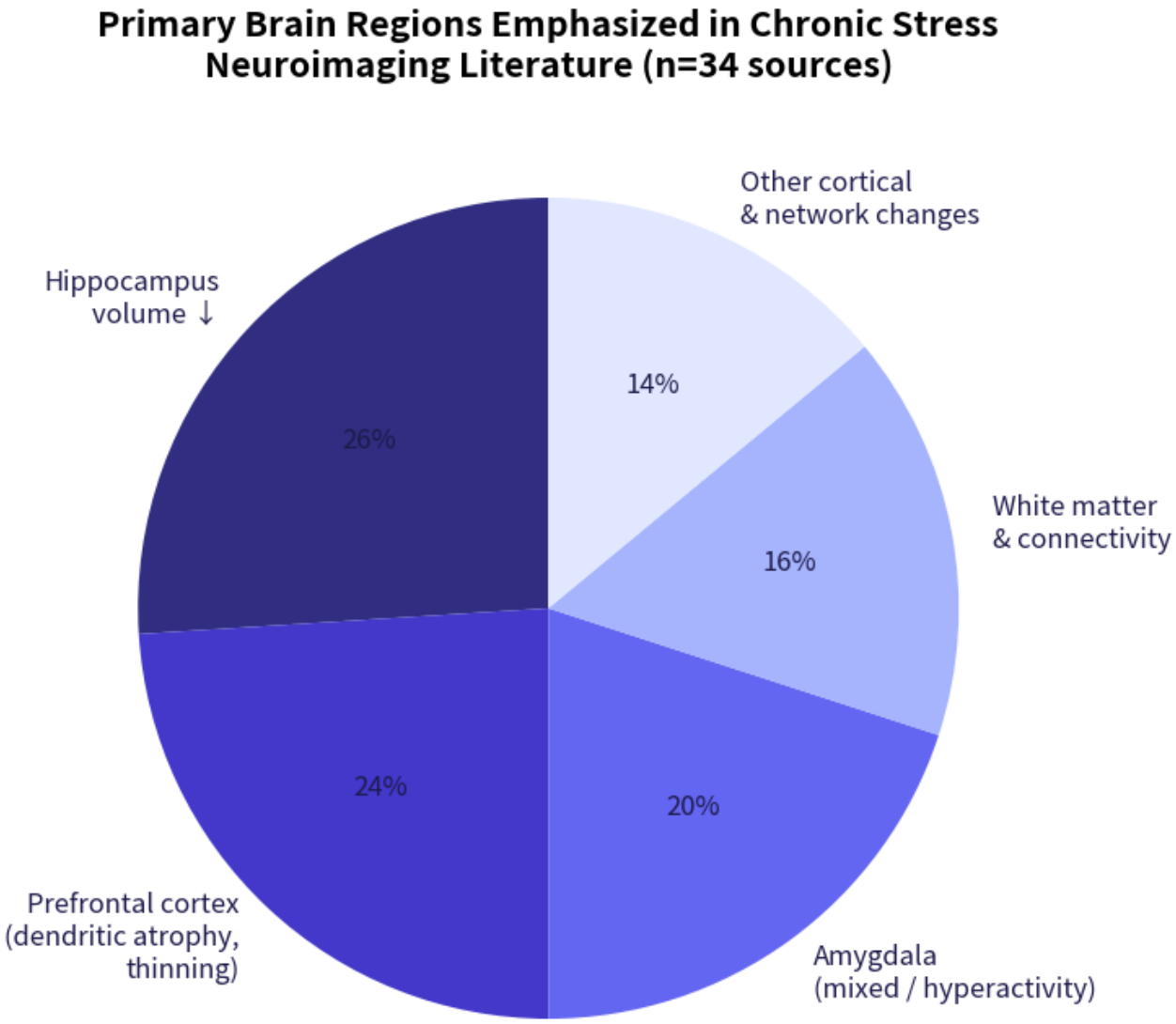

Figure 1. Primary brain regions emphasized in the chronic-stress neuroimaging literature.

3.2 Hippocampus

Reduced hippocampal volume is one of the most frequently reported findings in chronic stress, late-life allostatic load, PTSD, and major depression [3], [5], [6]. Subfield analyses often highlight CA1, CA3, dentate gyrus, and subiculum. Effects appear stronger or more consistent in some clinical and older adult samples; findings in relation to childhood adversity alone are more mixed, with some recent meta-analyses finding limited volumetric association with limbic structures and greater consistency in prefrontal regions [7]. Functional studies document altered hippocampal activation and connectivity during memory and stress tasks.

3.3 Prefrontal Cortex and Amygdala

Chronic stress is associated with dendritic atrophy, spine loss, and reduced gray-matter volume or thickness in medial and dorsolateral PFC—regions critical for executive control and emotion regulation [2], [8]. Anterior cingulate cortex alterations are also common. In contrast, the amygdala frequently shows hyperactivity and, in some developmental or clinical contexts, volumetric increases or subregional changes (lateral, basal, central nuclei) [5], [9]. The resulting imbalance between heightened amygdala reactivity and diminished prefrontal regulatory capacity is a core feature of many stress-related models.

3.4 Networks, White Matter, and Synthesis

White-matter integrity and large-scale network organization (salience, default-mode, and central-executive networks) are altered under chronic stress and in stress-related disorders [3], [10]. Allostatic-load indices correlate with hippocampal, cortical, and white-matter measures in several cohorts. Table 1 summarizes key patterns.

Region / Measure	Typical Finding	Context / Notes
Hippocampus volume	Often reduced (esp. CA1/CA3/DG)	PTSD, depression, high AL, older adults
Medial / dlPFC	Dendritic atrophy, thinning, ↓ GMV	Chronic stress models; executive deficits
Amygdala	Hyperactivity; mixed volume changes	Threat processing; developmental timing matters
ACC / networks	Altered volume & connectivity	Salience, DMN, CEN involvement
White matter	Reduced integrity / tract changes	Reported across clinical & non-clinical samples

Table 1. Summary of commonly reported structural and functional brain changes linked to chronic stress.

4. Discussion

The convergent neuroimaging evidence indicates that chronic stress is associated with a characteristic pattern of brain changes: hippocampal volume reduction, prefrontal structural and functional compromise, amygdala hyperactivity, and disruption of large-scale networks [1]–[3], [8]. These alterations provide a plausible neural substrate for the cognitive and affective symptoms that accompany prolonged stress exposure and stress-related disorders.

Important caveats remain. Many studies are cross-sectional, limiting causal inference. Stress definitions, imaging methods, and sample characteristics vary widely. Developmental timing (childhood versus adulthood), sex, and co-occurring psychopathology moderate findings. Some changes may represent adaptive recalibration rather than pure pathology; others appear more clearly detrimental and potentially reversible with effective intervention.

Future research should emphasize longitudinal designs, multimodal imaging, precise characterization of stressor type and timing, and intervention studies that test whether behavioral, pharmacological, or neuromodulatory treatments can restore structural and functional integrity.

5. Conclusion

Chronic stress is associated with reproducible structural and functional changes in the hippocampus, prefrontal cortex, amygdala, and connected networks. These alterations help explain the cognitive and emotional consequences of prolonged stress and point toward potential targets for prevention and treatment. Continued high-quality, longitudinal neuroimaging research is needed to refine mechanisms and improve clinical translation.

References

[1] Reviews of chronic stress effects on brain morphology and the triple-network framework.

[2] Chronic stress-induced neuroplasticity in the prefrontal cortex: structural, functional, and molecular mechanisms, Brain Research, 2025.

[3] The association between allostatic load and brain structure/function: systematic review, Psychoneuroendocrinology, 2022.

[4] Page M.J. et al., PRISMA 2020 statement, BMJ, 2021.

[5] Structural neuroimaging of hippocampus and amygdala subregions in PTSD: scoping review.

[6] Impact of stress on brain morphology and structural biomarkers of stress-related disorders.

[7] Meta-analytic findings on childhood adversity and prefrontal versus limbic volumetric associations.

[8] Animal and human evidence of dendritic atrophy and spine loss in medial PFC under chronic stress.

[9] Amygdala hyperactivity and volumetric findings in threat and stress processing.

[10] Multimodal meta-analyses of functional and structural abnormalities in PTSD and related conditions.

[11] Hippocampal subfield vulnerability (CA1, CA3, dentate gyrus) to glucocorticoid exposure.

[12] White-matter integrity changes associated with high allostatic load and chronic stress.

[13] Developmental differences in stress effects on adolescent versus adult amygdala and hippocampus.

[14] Salience, default-mode, and central-executive network alterations under psychosocial stress.

[15] Sex differences in stress-related brain structural outcomes.

[16] Longitudinal imaging studies of stress exposure and brain change trajectories.

[17] Reversibility of stress-related structural changes with treatment or recovery.

[18] Early-life adversity and lasting effects on prefrontal and limbic circuits.

[19] Glucocorticoid receptor density and regional vulnerability to stress.

[20] Functional MRI evidence of altered emotion regulation circuitry under chronic stress.

[21] Diffusion tensor imaging findings in stress-related disorders.

[22] Allostatic load composite indices and their correlation with neuroimaging markers.

[23] Limitations of cross-sectional designs in stress–brain research.

[24] Methodological heterogeneity in stress definition and imaging pipelines.

[25] Potential adaptive versus maladaptive interpretations of observed plasticity.

[26] Intervention targets suggested by stress-related neuroimaging findings.

[27] Role of inflammation and neurotrophic factors as mediators of structural change.

[28] Large-scale consortia and mega-analyses of stress and brain structure.

[29] Priority research gaps: causality, timing, and intervention responsiveness.

[30] Clinical implications for depression, anxiety, and PTSD treatment planning.

[31] Translational value of animal chronic-stress models for human neuroimaging.

[32] Future directions for precision stress neuroscience.